



EPiC Series in Health Sciences

Volume 4, 2020, Pages 201–203

CAOS 2020. The 20th Annual Meeting of the International Society for Computer Assisted Orthopaedic Surgery



# Kinematic Analysis of Total Knee Arthroplasty using Orthosensor system : Externally rotated femoral prosthesis versus Traditional design prosthesis

Seung-Min Na, Gun-Woo Kim, Nam-Hun Lee, Young-Woo Chung  
Jong-Keun Seon and Eun-Kyoo Song

Center for Joint Disease, Chonnam National University Hwasun Hospital  
seonbell1@chonnam.ac.kr


## Abstract

### 1. Introduction

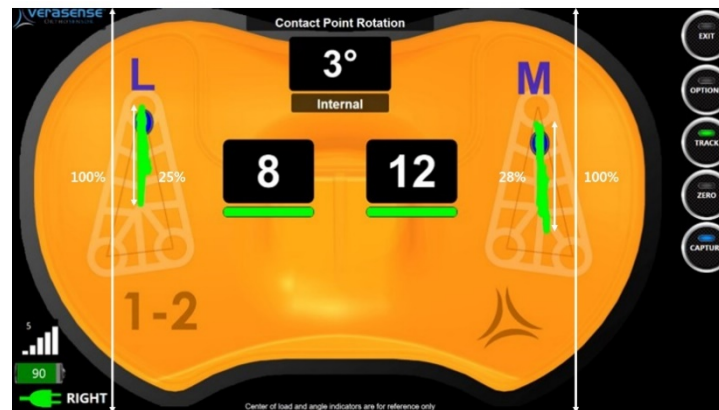
The purpose of this study was to elucidate kinematic change according to the implant's specific femoral rotation by using orthosensor implant with three degrees external rotation of femoral rotation rebuilt and traditional TKA implant without rebuilt of the femoral rotation.

### 2. Methods

Twenty-eight patients (34 knees) underwent TKA using traditional TKA implant and 16 patients (22 knees) underwent TKA using implant with three degrees external rotation of femoral rotation. Patients were followed up for at least 1 year. Mean age of patients was 71.1 years (range, 60 to 80 years) at the time of surgery. After implantation of femur and tibial components, we applied the orthosensor system, to evaluate femoral rollback of the new artificial joint. Femoral rollback was analyzed using digitized screenshot function of orthosensor system.



**Figure 1:** Tracking of the Femoral Component using Verasense.



**Figure 2:** Femoral Rollback Analysis.

### 3. Results

Overall femoral tracking proportion regardless of implants was significantly higher on the medial compartment compared to that on the lateral compartment ( $13.3 \pm 8.4\%$  vs.  $6.3 \pm 5.0\%$ ,  $p < 0.001$ ). Regarding femoral tracking according to each compartment, externally rotated femoral prosthesis and traditional prosthesis showed  $12.1 \pm 8.2\%$  and  $14.2 \pm 8.6\%$  ( $p = 0.371$ ) on the medial compartment and  $8.0 \pm 5.8\%$  and  $5.2 \pm 4.2\%$  ( $p = 0.059$ ) on the lateral compartment, respectively.

## 4. Conclusion

Our study showed reverse femoral roll-back movement with higher tracking distance on the lateral compartment during TKA. externally rotated femoral prosthesis TKA system with femoral component 3-degree rebuilt showed less roll-back difference between medial and lateral compartments compared to traditional TKA system. Fortunately, both TKA systems had excellent short-term clinical outcomes without having significant difference between the two. With longer follow-up and larger cohort, the advantage and effectiveness of femoral component rotation can be elucidated in the future.

## References

- Grazette AJ, Wylde V, Dixon S, Whitehouse SL, Blom AW, Whitehouse MR (2018) A 15 to 17-year follow-up of the Kinemax total knee replacement. *Knee* 25(6):1292-1298.
- Verlinden C, Uvin P, Labey L, et al. (2010) The influence of malrotation of the femoral component in total knee replacement on the mechanics of patellofemoral contact during gait: an in vitro biomechanical study. *J Bone Joint Surg Br* 92(5):737-742.
- Insall JN, Scuderi GR, Komistek RD, et al. (2002) Correlation between condylar lift-off and femoral component alignment. *Clin Orthop Relat Res* 403:143-152.
- Nodzo SR, Franceschini V, Gonzalez Della Valle A (2017) Intraoperative Load-Sensing Variability During Cemented, Posterior-Stabilized Total Knee Arthroplasty. *J Arthroplasty* 32(1):66-70.
- Kim HY, Kim KJ, Yang DS, et al. (2015) Screw-Home Movement of the Tibiofemoral Joint during Normal Gait: Three-Dimensional Analysis. *Clin Orthop Surg* 7(3):303-309.
- Bytyqi D, Shabani B, Lustig S, et al. (2014) Gait knee kinematic alterations in medial osteoarthritis: three dimensional assessment. *Int Orthop* 38(6):1191-1198.
- Koga Y (2015) Three-dimensional motion analysis and its application in total knee arthroplasty: what we know, and what we should analyze. *J Orthop Sci* 20(2):239-249.
- Siston RA, Giori NJ, Goodman SB, Delp SL (2006) Intraoperative passive kinematics of osteoarthritic knees before and after total knee arthroplasty *J Orthop Res.* 24(8):1607-1614